

Clinical and biological aspects of rotator cuff tears

Alessio Giai Via¹
 Mauro De Cupis¹
 Marco Spoliti²
 Francesco Oliva¹

¹ Department of Orthopaedic and Traumatology, University of Rome "Tor Vergata", School of Medicine,

² Department of Orthopaedics and Traumatology, San Camillo-Forlanini Hospital

Corresponding author:

Francesco Oliva
 Department of Trauma and Orthopaedic Surgery
 University of Rome "Tor Vergata"
 School of Medicine
 Viale Oxford, 81
 00133 Rome, Italy
 e-mail: olivafrancesco@hotmail.com

Summary

Rotator cuff tears are common and are a frequent source of shoulder pain and disability. A wide variation in the prevalence of rotator cuff tears has been reported. The etiology of rotator cuff tear remains multifactorial and attempts to unify intrinsic and extrinsic theories tried to explain the etiopathogenesis of rotator cuff tears. Knowledge of the etiopathogenesis of rotator cuff tears is important to improve our therapies, surgical techniques and promote tendon repair. Several strategies have been proposed to enhance tendon healing and recently research has focused on regenerative therapies, such as Growth Factors (GFs) and Plasma Rich Platelet (PRP), with high expectations of success.

KEY WORDS: rotator cuff tears, shoulder, growth factors, platelet rich plasma.

Introduction

Smith JG first reported rotator cuff tears (RCTs) in the London Medical Gazette in 1834¹. Many studies have been conducted in symptomatic and asymptomatic patients, also imaging and cadaveric studies have been performed. Cadaver studies in the elderly estimate the prevalence of full thickness tears ranging from 5% to 30%². Two prospective studies, one

performed with Magnetic Resonance Imaging (MRI) and the other with ultrasonography, investigated the prevalence of RCTs in individuals without pain and with apparently normal function. In the first study, Sher et al. reported that 28% of patients older than 60 years had a full-thickness tear³. In the second study Milgrom reported an ultrasonographic prevalence of 65% of RCTs in patients older than 70⁴. In 2006 Reilly published a review on cadaveric and imaging prevalence of RCTs⁵. The overall prevalence was 23% in 4629 cadaveric shoulders. The prevalence of RCTs increases linearly with age from the third decade, rising from 33% in the 40s to 55% in the 50s according to Milgrom⁴.

Physical examination

The clinical diagnosis is not always easy. Painful conditions of the long head biceps⁶ or acromioclavicular joint may result in high false positive rate⁷. The clinical presentation of rotator cuff (RC) pathology is extremely variable. A recent review concluded that RCTs are frequently asymptomatic⁷. Such variation in clinical features is a question that remains to be answered. Physical examination should include inspection, palpation, the evaluation of active and passive range of motion, the execution of strength and provocative tests. While strength may be normal in some patients with small full-thickness RCTs, weakness is usually present with larger tears. Many specific clinical tests are recorded to test muscles forming the RC. The most commonly used are the Jobe's test for supraspinatus tendon, the external rotation lag sign (ERLS) and the drop arm test for the assessment of the infraspinatus⁸. The Gerber's lift-off test, internal rotation lag sign (IRLS) and belly-press test are useful to evaluate subscapularis tears⁸. The ERLS, described by Hertel et al.⁹ in 1996, has been recently re-evaluated. When the test is performed correctly at 20° of abduction, the ERLS had a sensitivity of 56% and a specificity of 98% for isolated full-thickness supraspinatus tears, and when the lesion involved the infraspinatus and the tears minor the sensitivity improved substantially¹⁰. The ERLS is highly specific and acceptably sensitive for diagnosis of full-thickness tears, even in isolated lesion of the supraspinatus tendon. O'Brien test, Speed test and Yergason test are useful to assess the long head biceps^{9,11}. Murrel and Walton compared the results of 23 commonly used shoulder tests¹². Patients affected by shoulder pain, and who tested positive for supraspinatus weakness, weakness in external rotation,

Table 1. Extrinsic and intrinsic theories about etiopathogenesis of rotator cuff tears (RCTs).

Theory	References by first Author	Year
<i>Extrinsic factors</i>		
Chronic impingement syndrome	Neer ²³	1972
Overuse	Codman ²² McMaster ²⁵	1931, 1993
Multifactorial	Soslowsky ³²	2004
<i>Intrinsic factors</i>		
Hypoperfusion theory	Uthoff ⁴¹	1990
Degenerative theory	Sano ⁵⁰	1999
Degeneration-microtrauma	Yadav ⁵³	2009
Apoptotic theory	Yuan ⁵⁴	2002
Extra cellular matrix modifications	Riley ⁶⁰	2002

and impingement, have a 98% chance of rotator cuff tear. If patients were older than 60 years and two clinical tests were positive, the probability to be affected by a RCT was 98%. Any patient with a positive drop-arm sign also has a 98% chance of RCT. If only one of the three tests was positive, the clinical result was indeterminate and imaging was needed. If none of these clinical features were present, the chance of having a tear decreased to 5%. The authors concluded that the predictive power of the combined clinical tests is similar to the best values for magnetic resonance imaging and ultrasonography.

Bilateral rotator cuff tears and reruptures

Often a symptomatic RCT is associated with an asymptomatic tear in the contralateral shoulder¹³. Yamaguchi et al.¹⁴ showed that 35.5% of the patients who presented with a full-thickness tear on the painful side had a full-thickness tear on the non painful, contralateral side. In contrast, if a patient had either a partial thickness tear or a normal RC on the painful side, the rate of a full-thickness tear on the asymptomatic side was low, respectively 4.3% and 0.5%. The authors also affirmed that the size of a tear could be an important factor in the development of symptoms, and that it seems to be a trend toward a correlation between tear size progression and the development of new symptoms. They therefore recommend surveillance at yearly intervals for patients with known RCT that are treated nonoperatively. Rerupture or structural failure after RC repair is a

well-known complication. Many authors have investigated tendon rerupture in an attempt to determine its prevalence and significance, and the high rate of rerupture should be kept in mind after surgical repair. A rate of retear from 13% to 68% is reported in the literature after open RC repair^{15,16}. Mellado reported a prevalence of rerupture of 57.6% in a MR-based study¹⁷. The overall prevalence of rerupture of supraspinatus tendon was 46%. They also found that tear size and degree of preoperative muscle fatty degeneration affect rerupture prevalence. No statistically significant differences were found between arthroscopic and mini-open RC repair, and a study published in 2010 confirmed this result¹⁸. Recently Jost and Gerber described the clinical long-term outcomes after structural failure of RC repairs¹⁹. They saw that these patients had significant improvement in terms of pain, function, and strength, compared with the preoperative state, and they saw no clinical deterioration over time. They also found that the sizes of the retear did not increase in contrast to the natural history of untreated tears.

The etiopathogenesis of rotator cuff tears

Many theories have been proposed to explain the etiology of RCTs, which have been traditionally classified into 'extrinsic' and 'intrinsic' (Tab. 1). Historically, in 1922 Meyer suggested that tendon and capsular tears could be secondary to frictional contact of the greater tuberosity on the acromion²⁰. This theory was in contrast with the one proposed by Lindblom in

1939²¹, where the injury was thought to be caused by tension in the fascicles of the tendon aponeurosis. Later, Codman underlined the contribution of trauma to tendon injury²², and finally Neer²³ described his chronic impingement syndrome theory in 1972.

Extrinsic factors

The chronic impingement syndrome theory described by Neer is the best-known extrinsic pathological factor in RCTs. He said that the impingement of the RC against the undersurface of the acromion and coracoacromial (CA) ligament was the primary factor in causing tendon tears. In support to his theory, three distinct acromial shapes have been described by Bigliani: type I or flat acromion, type II or curved, and type III or hooked acromion²⁴. The last type would be associated with rotator cuff tears in 70% of cases. According to this theory, when surgical intervention was indicated, subacromial decompression has been widely performed. Other important extrinsic factors include mechanical overuse²⁵, anterior glenohumeral dislocations and fractures of the great tuberosity. Any process that impairs tissue healing also concur to cuff disease. Galatz demonstrated that nicotine has a deleterious effect on tendon healing²⁶, and smokers are less likely to respond favourably to cuff repair operations, with reduced postoperative function and satisfaction compared to non smokers²⁷. Diabetes is a risk factor for rotator cuff tears²⁸. In a study on asymptomatic subjects Abate et al. found that age-related RC tendon changes are more common in diabetics²⁹. Diabetic patients show a restricted shoulder range of motion, higher incidence in retears after a surgical repair, and higher rate of complications and infections are reported both after open and arthroscopic repair of RCT^{30,31}. An association between obesity and RCTs has also been proposed³². Congenital subacromial stenosis is a rare abnormality of the subacromial arch and may predispose to impingement³³.

Currently RCTs are considered to be multifactorial in etiology, and the relative contributions of these factors remain to be determined. Soslowsky, in his study on animal model, observed that the role of extrinsic compression or overuse factors without an additional factor may be insufficient to cause tendinopathy and that an extrinsic compression, like a type III acromion, did not cause injury of the RC tendons until overuse activity was introduced³⁴. More recently the preponderance of evidence strongly suggests that intrinsic acromial compression is not the primary cause of RC pathology. Clinical and cadaveric studies have found that the majority of pathologic changes occur on the articular side of the supraspinatus and infraspinatus tendon insertions, away from the acromion³⁵. This finding was confirmed by Buddoff et al.³⁶. He also supposed that once RC damage and weakness occurs, the tendons are unable to effectively oppose the superior shear stresses imparted by the larger and

stronger deltoid muscle. This leads to dynamic superior instability of the humeral head with arm elevation. This inappropriate superior migration of the humeral head causes secondary impingement of the RC against the CA arch. Although subacromial impingement does occur, the authors consider it a secondary process. Moreover, secondary to the RC dysfunction, the CA ligament may experience increased tensile stress and undergo degenerative changes, forming a reactive traction spur at its insertion into the antero-medial corner of the acromion³⁷. This traction spur is often mistaken for an abnormal acromial hook, or type 3 acromion. Actually many authors consider acromial spurs the consequence and not the cause of cuff degeneration and tearing^{38,39}. In addition spur may reform following subacromial decompression, implying that acromial changes are the result of RC pathology⁴⁰.

Intrinsic factors

Recent evidence strongly suggests that most of RCTs is caused by primary intrinsic degeneration. Several anatomic and surgical investigations with histologic sections have been performed to clarify the pathogenesis.

A hypovascular zone has been traditionally described at 10-15 mm proximal to the insertion of the supraspinatus tendon⁴¹. It remains unclear whether this hypoperfusion contributes to degeneration of the tendon. Goodmurphy et al. demonstrated that no significant difference in the microvasculature at the edge of the tear compared with control specimens, but there was increased vascularity 2.5 to 5 mm away from the tear⁴². Moseley and Goldie examined capillary distributions in cuff specimens and concluded that no hypovascular areas exist⁴³. Brooks showed that both vessel diameter and number were approximately reduced by a third at 5 mm from the cuff edge compared with 30 mm, but no significantly hypovascular areas exist⁴⁴. Indeed histologic, immunohistochemical and intraoperative doppler flowmetry analysis reported relative hyperperfusion at the area of the critical zone,⁴⁵ and laser doppler flowmetry studies showed hyperaemic response at the edge of the tear⁴⁶. These data suggest that area close to tendon tear is not hypovascular, and Goodmurphy affirmed that the avascularity of the critical zone may be an artifact of techniques used during prior cadaveric studies⁴².

More than seventy years ago Codman proposed degenerative theory for RCTs⁴⁷ understanding the importance of degenerative changes of the RC in the pathogenesis of tendon tears. This theory has been currently confirmed. Histopathologic studies on stumps of torn RCTs and on cadavers revealed thinning and disorientation of collagen fibers, myxoid degeneration, hyaline degeneration, chondroid metaplasia, calcification, vascular proliferation, and fatty infiltration^{48,49}. The frequency and distribution of these

degenerations suggest that they are common changes involved in the early degeneration of RC tendons before tearing occurs⁵⁰.

Enthesopathy also occurs in RC tendons degeneration. The normal enthesis is composed of four layers: tendon, unmineralized fibrocartilage, mineralized fibrocartilage, and bone. Between the two fibrocartilaginous layers the blue line or tidemark (the line of provisional calcification) can be recognized, but enthesis lost this spatial orientation in case of tendon degeneration. The insertion of collagen bundles into bone is interrupted by nests of granulation tissue, collagen bundle tears, blue line interruptions, and areas of stippled calcification⁵¹. A direct correlation between the degree of degeneration and the tensile strength was demonstrated, causing tendon tears⁵². So the degeneration-microtrauma theory was developed⁵³. This is a model that supposes age-related tendon damage compounded by chronic microtrauma results in partial tendon tears that then develop into full RCT. Typically after the deep fibers tear, they retract because they remain under tension, even with the arm at rest. This results in an increased load on the remaining fibers that increases the likelihood of further rupture.

Yuan and Murrell were the first authors to recognize apoptosis in rotator cuff tendon disorders⁵⁴. In their study they found an increase of apoptotic cells in degenerative supraspinatus tendon (34%) compared with normal subscapularis tendon (13%). Excessive apoptosis detected in degenerative rotator cuff tissue were confirmed by the DNA laddering assay, and they found that the majority of apoptotic cells were fibroblast-like cells. The role of apoptotic cells in RCT is not clear. The reduced number of functional fibroblasts/fibrocytes may contribute to impaired collagen metabolism culminating in RC degeneration. The increased number of apoptotic cells in degenerative tendon could affect the rate of collagen synthesis and repair. Impaired or dysfunctional protein synthesis may lead to weaker tendon and eventually increase the risk for rupture.

Many studies advocate the importance of extra cellular matrix (ECM) for the homeostasis of connective tissue. ECM is the substrate to which cells adhere, migrate and differentiate. ECM imparts information to cells and tissues by providing cell-binding motifs in its own proteins or by presenting growth factors and morphogens to the cells⁵⁵. Physiologic and pathologic modifications of the ECM seem the most important intrinsic factors involved in tendinopathies and tendons ruptures. Transglutaminase (TGs) have been implicated in the formation of hard tissue development, matrix maturation and mineralization⁵⁶. Nine different TGs have been found in mammalian. TG2, also known as tissue transglutaminase, is widely distributed within many connective tissues, and it has been implicated in organogenesis, tissue repair and in tissue stabilisation. Injured supraspinatus tendons showed reduction of TG2 protein expression, both at mRNA and protein level⁵⁷. TG are important in main-

taining the structural integrity of tendons thanks to its mechanical or crosslinking function in normal condition, and the fall of TG2 may mean the exhaustion of the reparative tendon's capabilities. The turnover of ECM in normal tendon is also mediated by matrix metalloproteinases (MMPs), such as collagenases and stromelysins⁵⁸. They are able to denature collagen type I. The turnover of ECM is mediated by the activity of MMP-1, MMP-2 and MMP-3⁵⁹. After tendon rupture, activity of MMP-1 increase while a reduction of MMP-2 and MMP-3 have been showed⁶⁰. An increase in MMP-1 activity and degradation of the collagen fibril network is a potential cause of the weakening of the tendon matrix and may contribute to a mechanically less stable tendon that is susceptible to rupture. These findings may represent a failure of the normal matrix remodelling process. Riley think that tendon degeneration is an active, cell-mediated process that may result from a failure to regulate specific MMP activities in response to repeated injury or mechanical strain⁶⁰.

Histologic studies of RCTs, as well as in other tendons injury, showed the absence of acute inflammatory cells^{48,61,62,63}, but this argument is still debated. Cetti and Matthews are not agree with this assertion, as they found histological evidence of inflammation using immunocytochemical methods respectively in Achilles tendons⁶⁴ and RC⁶⁵. In particular Matthews et al.⁶⁵ studied cellular and vascular changes in full thickness tears of the RC. They found evidence of chronic inflammatory within the RC tendons and histological changes indicative of repair, as increased fibroblast cellularity and blood vessel proliferation. But they also found that both the number of inflammatory cells and the fibroblast population decrease as the size of the RCTs increase. The authors concluded that RCTs have the potential to heal, but this reparative process diminishes as the tear size increases. May be, they also affirmed, that in earlier studies of ruptured rotator tendon specimens, inflammatory cells were present but had simply not been identified. Animal studies demonstrated that fatty degeneration of the muscle progresses with time after RC tendon detachment^{66,67}. Fatty degeneration of supraspinatus and infraspinatus human tendon is strongly associated with the tear size and location⁶⁸.

Histopathologic and morphological classifications of RCTs

While many epidemiological, etiopathogenetical studies have been performed during the last decade, relatively few studies tried to quantify the histopathological findings of tendon tears. In 2001 Riley et al analyzed 118 supraspinatus tendons from patients with RCTs⁶⁹. The authors proposed a four-point scale based on the organization of the tendon fibre bundles, the aspect of tenocytes nuclei and the grade of hyalinization (Tab. 2). Using this histopathological grading system they found that the severity of tendon

Table 2: Histopathological grading system of rotator cuff degeneration according to Riley.

	Organization of the tendon fibre bundles	Tenocyte nuclei	Grade of hyalinization
GRADE 1 Normal tendon	The fibres bundles are well oriented with a wavy outline. Individual fibers are easily discernible within the bundles.	Nuclei are elongated with an unremarkable chromatin pattern. Nuclei lay with their long axis parallel to the bundles of collagen.	No hyalinization.
GRADE 2 Mild degeneration	Collagen fibres are relatively well aligned but the waviness is patchy.	Cell nuclei are shorter but still oval. Darker-staining chromatin can be observe. The nuclei often are arranged in short chains to give Indian-file appearance.	No hyalinization.
GRADE 3 Moderate degeneration	Loss of orientation of the collagen bundles.	Cell nuclei are round or oval shaped and often increase in number. There is a loss of orientation of nuclei in relation to collagen bundles. The chromatin is darkly stained.	Moderate hyalinisation, areas of smudgy, homogeneous eosinophilic staining in haematoxylin /eosin preparation.
GRADE 4 Severe degeneration	Complete loss of orientation of the collagen bundles.	The nuclei are loss in number, small, dark and rounded.	Diffuse hyalinization with a homogeneous appearance.

matrix degeneration increased with age and that more severe degeneration is associated with the development of tendinopathy. Two other scoring systems are present in literature: the Movin score⁷⁰ and the Bonar score⁷¹. These two scales were originally developed for Achilles and patellar tendon respectively, but recently they have been modified and validated for RC histopathological assessment (Tab. 3). Lo and Burkhart described a morphological classification of RCTs based on arthroscopic observations⁷². The authors classified RCTs into four categories: crescent-shaped, U-shaped, L-shaped, and massive, contracted and immobile tears (Fig.1). This classification help the surgeon to understand the tear patterns and to repair it.

Rotator cuff healing

Tendon healing is a complex and orchestrated series of physiological events involving synthesis, migration, and degradation of extracellular matrix components. Many studies have been performed in order to examine the effects of mobilization and disuse on tendon healing⁷³. Tendons that are immobilized have been shown to promote adhesion, but exhibit decreased mechanical properties and deter functional recovery^{74,75}. Mobilization after repair instead promote cellular activity, improved tensile properties and enhanced gliding function. Tendons undergoing controlled passive motion after repair showed superior

tensile properties and gliding function when compared to immobilized tendons⁷⁶. Deficient scarring may lead to premature rupture at the injury site and immobilization can contribute to healing and scar formation, but excessive scarring can restrict tendon gliding. Therefore, a fine balance exists between the progression of tendon healing and applying mobilization.

Another important controversy is the ability the tendon to heal because tendon tissue shows only a repair but no regeneration²⁸. Some histological studies showed no cellular or vascular proliferation of the stumps⁷⁷ while others animal studies revealed the presence of multinucleated giant cells⁷⁸. These cells are involved in resorption but not repair, confirming the idea that the tendons do not contribute to healing. On the other hand some authors stated that RCTs have the potential to heal⁶⁵. Studies *in vitro* pointed out the increase of procollagen synthesis without an increase in cell number⁷⁹, while immunocytochemical analysis showed that cells retain their ability to produce type I procollagen⁸⁰. The authors concluded that tissue adjacent to RCT (2.5 mm) appears to be histologically viable in both microvasculature, as previously described, and cellular synthesis of type I procollagen. They advise to avoid to trimmed the edges of the torn rotator cuff before attachment. Jost and Gerber⁷ in their long-term follow-up after structural failure of rotator cuff repairs surprising observed the compelling evidence that small reruptures, smaller that 400 mm², have a potential to heal.

Table 3: Histopathological classification of RC tendinopathy (Bonar Score).

	Tenocytes	Ground substance	Collagen	Vascularity
GRADE 0	Inconspicuous elongated spindle shaped nuclei with no obvious cytoplasm at light microscopy.	No stainable ground substance.	Collagen arranged in tightly cohesive well demarcated bundles with a smooth dense bright homogeneous polarization pattern with normal crimping.	Inconspicuous blood vessels coursing between bundles.
GRADE 1	Increased roundness: nucleus becomes more ovoid to round in shape without conspicuous cytoplasm.	Stainable mucin between fibers but bundles still discrete.	Diminished fiber polarization: separation of individual fibers with maintenance of demarcated bundles.	Occasional cluster of capillaries, less than one per 10 highpower fields.
GRADE 2	Increased roundness and size: the nucleus is round, slightly enlarged and a small amount of cytoplasm is visible.	Stainable mucin between fibers with loss of clear demarcation of bundles.	Bundle changes: separation of fibers with loss of demarcation of bundles giving rise to expansion of the tissue overall and clear loss of normal polarization	1-2 clusters of capillaries per 10 high power fields.
GRADE 3	Nucleus is round, large with abundant cytoplasm and lacuna formation (chondroid change).	Abundant mucin throughout with inconspicuous collagen staining.	Marked separation of fibers with complete loss of architecture.	Greater than two clusters per 10 highpower fields.

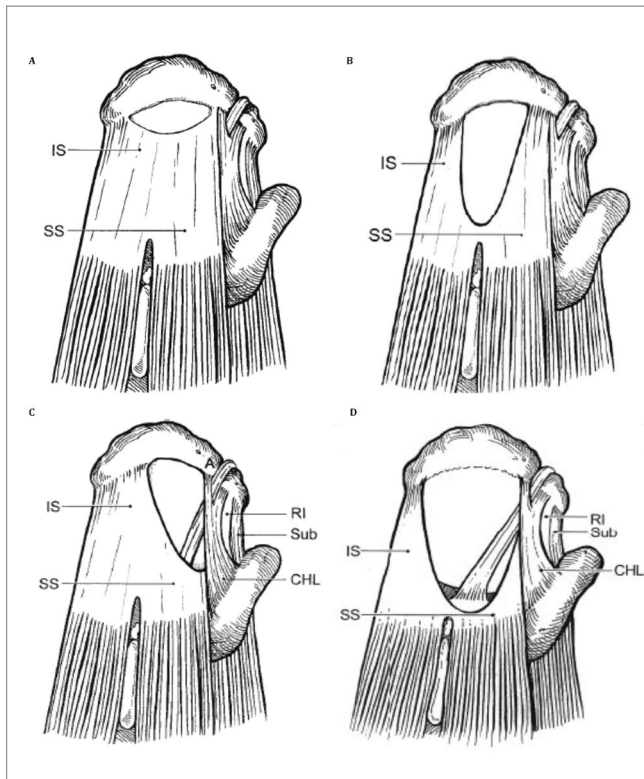
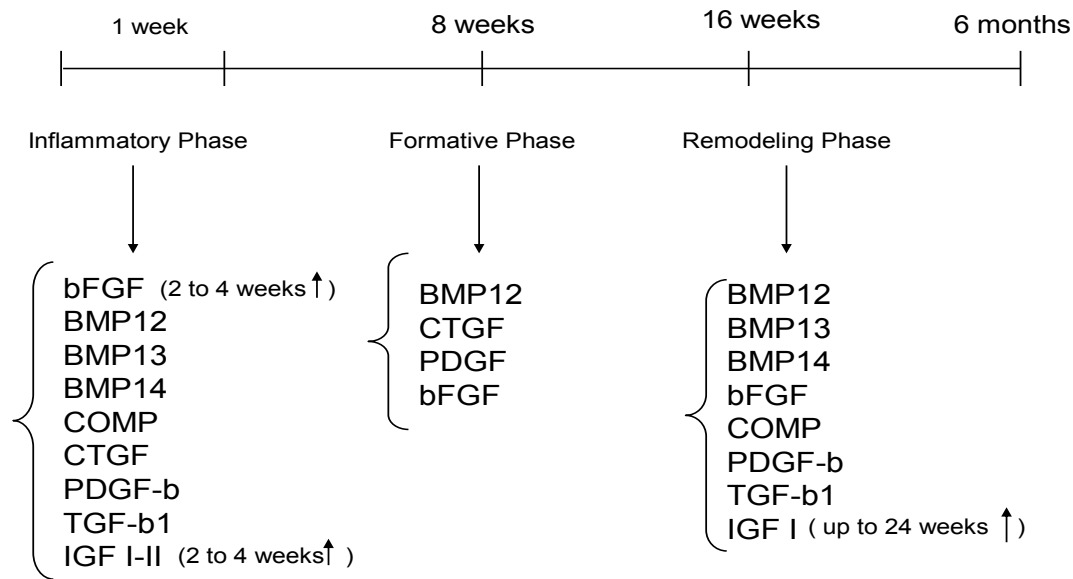


Figure 1. Morphological classifications of rotator cuff tears. A) crescent-shaped. B) U-shaped. C) L-shaped. D) massive tears. Supraspinatus tendon (SS); infraspinatus (IS) tendon; rotator interval (RI); subscapularis tendon (Sub); coracohumeral ligament (CHL).

Table 4: Expression of growth factors over 6 months tendon healing.



The healing process of all tendons passes through three well defined stages. Growth factors are expressed during all these phases, promoting cell proliferation, extracellular matrix production and also participating to the final remodeling of the tendon. This figure shows the timing of some Growth factors studied. It is possible that, in the next future, it will be modified after new investigations, but it such timings must be kept in mind, because the addition of a given growth factor too early or too late in the tendon healing process may decrease their effectiveness.

Abbreviations: PDGF: platelet-derived growth factor; EGF: Epidermal growth factor; IGF-1: insulin-like growth factor-1; BMP: bone morphogenic protein; GDF: growth differentiation factor; CTGF: connective tissue growth factor; VEGF: Vascular endothelial growth factor; HGF: hepatocyte growth factor mRNA: messenger ribonucleic acid; FGF: Fibroblast growth factor; AFA: Autologous fibrin adhesive; PRP: Platelet rich plasma; TGF-beta: transforming growth factor-beta; BMP: Bone morphogenetic proteins; CDMP: Cartilage-derived morphogenetic proteins; MMP: matrix metalloproteinase; hsp47: Heat shock protein 47; VEGF: vascular endothelial growth factor; Smad: Small Mothers Against Decapentaplegic; bFGF: basic fibroblast growth factor; IGFBBPs: Insulin-like growth factor binding proteins; PDGFBB: Platelet-derived growth factor isoform B; ESWT: Extracorporeal shock wave therapy; iNOS: inducible nitric oxide synthase; TIEG: TGF-β inducible early gene; AAV: adeno-associated virus-mediated; PIGF: Placenta growth factor.

It is very important provide the tendon the best conditions to heal. The subacromial bursa seems to play an important role. In normal conditions it has three functions: it facilitates gliding between two layers of tissue, provides blood supply to the cuff tendons and provides cells and vessels to the healing process after surgical repair. The bursa is never affected in its entirety and intraoperative observations clearly showed that the bursal thickening is limited to the site of tear⁸¹. Codman noted that the outer, more superficial wall of the bursa always remains normal⁴⁷. Actually many authors recommend to preserve the bursa, and bursectomy exclusively in order to improve exposure prior to repairing the torn cuff, as performed by many surgeons, should be avoid^{82,51}. Anterior acromioplasty may also produce negative long-term effects if performed routinely. Some surgeons argue that such a procedure may prevent later cuff tearing. In a prospective study Hyvonen et al. clearly showed that anterior acromioplasty does not prevent later tearing⁸³. As a result of anterior acromioplasty we not only remove the anterior part of the acromion but also the coracoacromial ligament and the fibers of the coracoacromial ligament that blend into the coraco-

humeral ligament, causing superior and inferior shoulder instability than allow the humeral head to migrate superiorly⁸⁴. Another important factor for tendon healing is the enthesis. The changes occurring at the enthesis was investigate in an experiment study on rabbits⁷⁸. Six weeks after surgical repair of rotator cuff the appearance of the fibrocartilage was observed and typical columns of chondrocytes were seen after 12 weeks. During fibrocartilage re-formation the site of repair is vulnerable to tearing and must therefore be protected against high stress. In clinical practice the authors suggest careful rehabilitation for the first 8 weeks, including passive and active assisted exercises, and that strenuous exercises should be avoided. Several strategies have been proposed to enhance tendon healing. Recently research has focused on regenerative therapies such as Growth Factors (GFs) and Plasma Rich Platelet (PRP). The role of growth factor in the complex process of tendon healing has been clarified in a recent review⁸⁵. In vitro studies showed that the addition of PRP to human tenocytes resulted in cell proliferation, collagen deposition and improved gene expression for matrix degrading en-

zymes and endogenous growth factors⁸⁶. They also stimulate tendon healing by a well-ordered angiogenesis⁸⁷. However some authors highlights the importance to understand the timing of administration of growth factors (Tab. 4) and their dosage for designing effective GF therapy⁸⁵. Few clinical studies have been reported in literature up to date. Castricini et al.⁸⁸ performed a randomized double blind controlled trial with 88 patients and they found no statistically significant difference at 16-months follow-up. They stated that the study does not support the use of PRP in small to medium sized RCTs. Similar results have been reported also by Rodeo et al.⁸⁹. Even if autologous PRP is safe and there is some evidence that it may improve pain after arthroscopic RCTs repair at short term follow-up⁹⁰, PRP has not been shown to improve healing rates in rotator cuff tears and the data do not support routine use of PRP in RC repair^{88,89}.

The use of non-steroidal anti-inflammatory drugs (NSAIDs) is common in clinical practice but their use for the treatment of tendinopathy is debated. It has been shown that NSAIDs inhibit Prostaglandin and collagen synthesis during exercises, and that adhesion formation was reduced in healing tendon⁹¹. *In vitro* studies also showed that tenocytes proliferation was impaired and MMPs expression was induced by NSAIDs^{91,92}. The results of these studies suggest that NSAIDs therapy might interfere with the natural tendon healing.

Conclusions

RCTs are common and they are frequently asymptomatic. RCTs demonstrated during radiological investigation of the shoulder may not be responsible for the presenting symptoms, so it is important to correlate radiological and clinical findings. Emerging studies have elucidated the complex process of RC degeneration and the attempts to unify intrinsic and extrinsic theories can be made to explain the natural history of RCTs. Some RCTs have the potential to repair, in particular when they are small. A little evidence to support the use of injections with PRP in the treatment of RC rupture can be find in literature, but further studies using a proper control group, randomization, blinding and validated disease-specific outcome measures for pain and function are needed. In conclusion, exciting new findings in basic applied research can guide the shoulder surgeon. Hopefully, research efforts will continue to confirm or disprove the current ways by which we treat rotator cuff disease.

References

1. Smith JG. Pathological appearances of seven cases of injury of the shoulder joint with remarks. London Med Gaz 1834; 14:280.
2. Lehman C, Cuomo F, Kummer FJ, Zuckerman JD. The incidence of full thickness rotator cuff tears in a large cadaveric population. Bull Hosp Jt Dis 1995; 54:30-31.

3. Sher JS, Uribe JW, Posada A, Murphy BJ, Zlatkin MB. Abnormal findings on magnetic resonance images of asymptomatic shoulders. J Bone Joint Surg Am 1995; 77:10-15.
4. Milgrom C, Schaffler M, Gilbert S, Van Holsbeeck M. Rotator-cuff changes in asymptomatic adults. The effect of age, hand dominance and gender. J Bone Joint Surg Br 1995; 77:296-298.
5. Reilly P, Macleod I, Macfarlane R, Windley J, Emery R. Dead men and radiologists don't lie: a review of cadaveric and radiological studies of rotator cuff tear prevalence. Ann R Coll Surg Engl 2006; 88:116-121.
6. Park HB, Yokota A, Gill HS, El Rassi G, McFarland EG. Diagnostic accuracy of clinical tests for the different degrees of subacromial impingement syndrome. J Bone Joint Surg Am 2005; 87:1446-1455.
7. Jost B, Zumstein M, Pfirrmann CW, Gerber C. Long-term outcome after structural failure of rotator cuff repairs. J Bone Joint Surg Am 2006; 88:472-479.
8. Gerber C. Massive rotator cuff tears. In: Iannotti JP, ed. Disorders of the Shoulder. Philadelphia: Lippincott, Williams and Wilkins 1999; 57-92.
9. Hertel R, Ballmer FT, Lombert SM, Gerber C. Lag signs in the diagnosis of rotator cuff rupture. J Shoulder Elbow Surg 1996; 5:307-313.
10. Blonna D, Cecchetti S, Tellini A, et al. Contribution of the supraspinatus to the external rotator lag sign: kinematic and electromyographic pattern in an in vivo model. J Shoulder Elbow Surg 2010; 19:392-398.
11. Oliva F, Giai Via A, Rossi S. Short-term effectiveness of bi-phase oscillatory waves versus hyperthermia for isolated long head biceps tendinopathy. MLTJ 2011; 1:112-117.
12. Murrell GA, Walton JR. Diagnosis of rotator cuff tears. The Lancet 2001; 357:769-770.
13. Merolla G, Paladini P, Saporito M, Porcellini G. Conservative management of rotator cuff tears: literature review and proposal for a prognostic prediction score. MLTJ 2011; 1:12-19.
14. Yamaguchi K, Ditsios K, Middleton WD, Hildebolt CF, Galatz LM, Teefey SA. The demographic and morphological features of rotator cuff disease. A comparison of asymptomatic and symptomatic shoulders. J Bone Joint Surg Am 2006; 88:1699-1704.
15. Zumstein MA, Jost B, Hempel J, Hodler J, Gerber C. The clinical and structural long-term results of open repair of massive tears of the rotator cuff. J Bone Joint Surg Am 2008; 90:2423-2431.
16. Knudsen HB, Gelineck J, Sojbjerg JO, Olsen BS, Johansen HV, Sneppen O. Functional and magnetic resonance imaging evaluation after single-tendon rotator cuff reconstruction. J. Shoulder and Elbow Surg 1999; 8:242-246.
17. Mellado JM, Calmet J, Olona M et al. MR assessment of the repaired rotator cuff: prevalence, size, location, and clinical relevance of tendon rerupture. Eur Radiol 2006; 16:2186-2196.
18. Osti L, Papalia R, Paganelli M, Denaro E, Maffulli N. Arthroscopic vs mini-open rotator cuff repair. A quality of life impairment study. Int. Orthop 2010; 34:389-394.
19. Jost B, Zumstein M, Pfirrmann CW, Gerber C. Long-term outcome after structural failure of rotator cuff repairs. J Bone Joint Surg Am 2006; 88:472-479.
20. Meyer AW. Further observations on use-destruction in joints. J Bone Joint Surg 1922; 4:491-511.
21. Lindblom K. On pathogenesis of ruptures of the tendon aponeurosis of the shoulder joint. Acta Radiol 1939; 20:563-577.
22. Codman EA, Akerson IB. The pathology associated with rupture of the supraspinatus tendon. Ann Surg 1931; 93:348-359.
23. Neer C.S., 2nd. Anterior acromioplasty for the chronic im-

- pingement syndrome in the shoulder: a preliminary report. *J Bone Joint Surg Am* 1972; 5:441-450.
24. Bigliani LU, Morris DS, April EW. The morphology of the acromion and its relationship to rotator cuff tears. *Orthop Trans* 1986; 10:216.
 25. McMaster W, Troup T. A survey of interfering shoulder pain in United States competitive swimmers. *Am. J. Sports Med* 1993; 21:67-70.
 26. Galatz LM, Silva MJ, Rothermich SY, Zaegel MA, Havlioglu N, Thomopoulos S. Nicotine delays tendon-to-bone healing in a rat shoulder model. *J Bone Joint Surg Am* 2006; 88:2027-2034.
 27. Mallon WJ, Misamore G, Snead DS, Denton P. The impact of preoperative smoking habits on the results of rotator cuff repair. *J Shoulder Elbow Surg* 2004; 13:129-132.
 28. Wildemann B, Klatt F. Biological aspects of rotator cuff healing. *MLTJ* 2011; 1:161-168.
 29. Abate P, Schiavone C, Salini V. Sonographic evaluation of the shoulder in asymptomatic elderly subjects with diabetes. *BMC Musculoskeletal Disorders* 2010; 11:278.
 30. Clement ND, Hallett A, MacDonald D, Howie C, McBirnie J: Does diabetes affect outcome after arthroscopic repair of the rotator cuff? *J Bone Joint Surg Br* 2010; 92:1112-1117.
 31. Chen AL, Shapiro JA, Ahn AK, Zuckerman JD, Cuomo F. Rotator cuff repair in patients with type I diabetes mellitus. *J Shoulder Elbow Surg* 2003; 12:416-421.
 32. Wendelboe AM, Hegmann KT, Gren LH, Alder SC, White GL Jr. and Lyon JL. Associations Between Body-Mass Index and Surgery for Rotator Cuff Tendinitis. *J Bone Joint Surg Am* 2004; 86:743-747.
 33. Carr A, Harvie P. Rotator cuff tendinopathy. In: Maffulli N, Ranstrom P, Leadbetter WB. *Tendon Injuries. Basic science and clinical medicine* Springer 2005; 101-118.
 34. Soslowsky LJ, Thomopoulos LS, Esmail A et al. *Annals of biomedical engineering* 2002; 30:1057-1063.
 35. Ogata S, Uthoff HK. Acromial enthesopathy and rotator cuff tear. A radiologic and postmortem investigation of the coracoacromial arch. *Clin Orthop* 1990; 254:39-48.
 36. Budoff EF, Rodin D, Ochiai D, Nirschl RP. Arthroscopic Rotator Cuff Debridement Without Decompression for the Treatment of Tendinosis. *Arthroscopy: The Journal of Arthroscopic and Related Surgery* 2005; 21:1081-1089.
 37. Uthoff HK, Hammond I, Sarkar K, Hooper GJ, Papoff WJ. The role of the coracoacromial ligament in the impingement syndrome. A clinical, radiological and histological study. *Int Orthop* 1988; 12:1297-1304.
 38. Ozaki J, Fujimoto S, Nakagawa Y, Masuhara K, Tamai S. Tears of the rotator cuff of the shoulder associated with pathological changes in the acromion. A study in cadavera. *J Bone Joint Surg Am* 1998; 70:1224-1230.
 39. Uthoff HK, Trudel G, Himori K. Relevance of pathology and basic research to the surgeon treating rotator cuff disease. *J Orthop Sci* 2003; 8:449-456.
 40. Anderson K, Bowen MK. Spur reformation after arthroscopic acromioplasty. *Arthroscopy* 1999; 15:788-791.
 41. Lohr JF, Uthoff HK. The microvascular pattern of the supraspinatus tendon. *Clin Orthop* 1990; 254:35-38.
 42. Goodmurphy CW, Osborn J, Akesson EJ, et al. An immunocytochemical analysis of torn rotator cuff tendon taken at the time of repair. *J Shoulder Elbow Surg* 2003;12: 368-374.
 43. Moseley HF, Goldie I. The arterial pattern of the rotator cuff of the shoulder. *J Bone Joint Surg Br.* 1963; 45:780-789.
 44. Brooks CH, Revell WJ, Heatley FW. A quantitative histological study of the vascularity of the rotator cuff tendon. *J Bone Joint Surg Br* 1992; 74:151-153.
 45. Fukuda H, Hamada K, Yamanaka K. Pathology and pathogenesis of bursal-side rotator cuff tears viewed from en bloc histologic sections. *Clin Orthop Relat Res* 1990; 254:75-80.
 46. Swiontkowski MF, Iannotti JP, Boulas HJ, Esterhai JL. Intraoperative assessment of rotator cuff vascularity using laser Doppler flowmetry. In: Post M, Morrey BF, Hawkins RJ, eds. *Surgery of the shoulder*. St. Louis: Mosby-Year Book, 1990.
 47. Codman EA. Rupture of the supraspinatus tendon. In: *The shoulder*. Boston: Thomas Todd; 1934. p. 123-177.
 48. Hashimoto T, Nobuhara K, Hamada T. Pathologic evidence of degeneration as a primary cause of rotator cuff tear. *Clin Orthop Relat Res* 2003 ;415:111-120.
 49. Ozaki J, Fujimoto S, Nakagawa Y, et al. Tears of the rotator cuff of the shoulder associated with pathological changes in the acromion: a study in cadavera. *J Bone Joint Surg Am* 1998; 70:1224-1230.
 50. Sano H, Ishii H, Trudel G, et al. Histologic evidence of degeneration at the insertion of 3 rotator cuff tendons: A comparative study with human cadaveric shoulders. *J Shoulder Elbow Surg* 1999; 8:574-579.
 51. Uthoff HK, Guy Trudel, Ko Himori. Relevance of pathology and basic research to the surgeon treating rotator cuff disease. *J Orthop Sci* 2003; 8:449-456.
 52. Hashimoto T, Nobuhara K. Pathogenesis of the rotator cuff. *Nobuhara Hosp J.* 2000;104-8.
 53. Yadav H, Nho S, Romeo A, MacGillivray JD. Rotator cuff tears: pathology and repair. *Knee Surg Sports Traumatol Arthrosc* 2009; 17:409-421 57.
 54. Yuan J, Murrell GA, Wei AQ, Wang MX Apoptosis in rotator cuff tendinopathy. *J Orthop Res* 2002; 20:1372-1379.
 55. M. Chiquet, Regulation of extracellular matrix gene expression by mechanical stress, *Matrix Biol* 18 (1999) 417-426.
 56. Tarantino U, Oliva F, Taurisano G, Orlandi A, Pietrosi V, Candi E, Melino G, Maffulli N. FXIIIa and TGF-beta over-expression produces normal musculoskeletal phenotype in TG2-/-mice. *Amino Acids* 2009; 36(4):679-684.
 57. Oliva F, Zocchi L, Codispoti A, Candi E, Celi M, Melino G, Maffulli N, Tarantino U. Transglutaminases expression in human supraspinatus tendon ruptures and in mouse tendons. *Biochem Biophys Res Commun* 2009 Feb 20; 379(4):887-891.
 58. Dalton S, Cawston TE, Riley GP, Bayley IJ, Hazleman BL. Human shoulder tendon biopsy samples in organ culture produce procollagenase and tissue inhibitor of metalloproteinases. *Ann Rheum Dis* 1995; 54(7):571-577.
 59. Choi HR, Kondo S, Hirose K, et al. Expression and enzymatic activity of MMP-2 during healing process of the acute supraspinatus tendon tear in rabbits. *J Orthop Res* 2002; 20:927-933.
 60. Riley GP, Curry V, DeGroot J, van El B, Verzijl N, Hazleman BL, Bank RA. Matrix metalloproteinase activities and their relationship with collagen remodelling in tendon pathology *Matrix Biol* 2002; 21(2):185-195.
 61. Nirschl RP. Rotator cuff tendinitis: Basic concepts of pathoetiology. *Instr Course Lect* 1989; 38:439-445.
 62. Khan K, Cook J. The painful nonruptured tendon: Clinical aspects. *Clin Sports Med* 2003; 22:711-725.
 63. Ishii H, Brunet JA, Welsh RP, et al. "Bursal reactions" in rotator cuff tearing, the impingement syndrome, and calcifying tendonitis. *J Shoulder Elbow Surg* 1997; 6:131-136.
 64. Cetti R, Junge J, Vyberg M. Spontaneous rupture of the Achilles tendon is preceded by widespread and bilateral tendon damage and ipsilateral inflammation: a clinical and histopathologic study of 60 patients. *Acta Orthop Scand* 2003; 74:78-84.
 65. Matthews TJ, Hand GC, Rees JL, Athanasou NA, Carr AJ. Pathology of the torn rotator cuff tendon. Reduction in potential for repair as tear size increases. *J Bone Joint Surg Br* 2006; 88:489-495.
 66. Gerber C, Meyer DC, Schneeberger AG, Hoppeler H, von

- Rechenberg B. Effect of tendon release and delayed repair on the structure of the muscles of the rotator cuff: an experimental study in sheep. *J Bone Joint Surg Am* 2004; 86:1973-1982.
67. Rubino LJ, Stills HF Jr, Sprott DC, Crosby LA Fatty infiltration of the torn rotator cuff worsens over time in a rabbit model. *Arthroscopy* 2007; 23:717-722.
68. Kim HM, Dahiya N, Teefey SA, Keener JD, Galatz L M, Yamaguchi K. Relationship of tear size and location to fatty degeneration of the rotator cuff. *J Bone Joint Surg Am* 2010; 92:829-839.
69. Riley GP, Goddard MJ, Hazleman BL. Histopathological assessment and pathological significance of matrix degeneration in supraspinatus tendons. *Rheumatology* 2001; 40:229-230.
70. Movin T, Gad A, Reinholt F, Rolf C. Tendon pathology in long-standing achillobodynia. Biopsy findings in 40 patients. *Acta Orthop Scand* 1997; 68:170-175.
71. Cook J, Feller J, Bonar S, Khan K. Abnormal tenocyte morphology is more prevalent than collagen disruption in asymptomatic athletes' patellar tendons. *J Orthop Res* 2004; 22: 334-338.
72. Lo IK, Burkhart SS. Current concepts in arthroscopic rotator cuff repair. *Am J Sports Med.* 2003; 31:308-324.
73. Lin TW, Cardenas L, Soslowky LJ. Biomechanics of tendon injury and repair. *J Biomech.* 2004; 37:865-877.
74. Palmes D, Spiegel HU, Schneider TO et al. Achilles tendon healing: long-term biomechanical effects of postoperative mobilization and immobilization in a new mouse model. *Journal of Orthopaedic Research* 2002; 20, 939-946.
75. Murrell GA, Lilly III EG, Goldner RD, Seaber AV, Best TM. Effects of immobilization on achilles tendon healing in a rat model. *Journal of Orthopaedic Research* 1994; 12:582-591.
76. Feehan LM, Beauchene JG. Early tensile properties of healing chicken flexor tendons: early controlled passive motion versus postoperative immobilization. *Journal of Hand Surgery Am.* 1990; 15:63-68.
77. Fukuda H, Hamada K, Yamanaka K. Pathology and pathogenesis of bursal-side rotator cuff tears viewed from- en bloc histologic sections. *Clin Orthop* 1990; 254:75-80.
78. Uthoff HK, Sano H, Trudel G, et al. Early reactions after reimplantation of the tendon of supraspinatus into bone. *J Bone Joint Surg Br* 2000; 82:1072-1076.
79. Uthoff HK, Kumagai J, Sarkar K, Lohr J, Murnaghan P. Morphologic evidence of healing in torn human rotator cuffs. *J Bone Joint Surg Br* 1992; 74:293-294.
80. Goodmurphy CW, Osborn J, Akesson EJ, Johnson S, Stanescu V, Regan WD. An immunocytochemical analysis of torn rotator cuff tendon taken at the time of repair. *J Shoulder Elbow Surg* 2003; 12:368-374.
81. Ishii H, Brunet JA, Welsh RP, et al. "Bursal reactions" in rotator cuff tearing, the impingement syndrome, and calcifying tendonitis. *J Shoulder Elbow Surg* 1997; 6:131-136.
82. Bateman JE. Lesions producing shoulder pain predominantly. In: *The shoulder and neck*, 2nd edn. Toronto: Saunders; 1978. p. 242-374.
83. Hyvonen P, Lohi S, Jalovaara P. Open acromioplasty does not prevent the progression of an impingement syndrome to a tear: nine-year follow up of 96 cases. *J Bone Joint Surg Br.* 1998; 80:813-816.
84. Itoi E, Berglund LJ, Grabowski J, et al. Superior-inferior stability of the shoulder: role of the coracohumeral ligament and the rotator interval capsule. *Mayo Clin Proc* 1998; 73:508-515.
85. Oliva F, Via AG, Maffulli N. Role of growth factors in rotator cuff healing. *SMAR* 2011; 19:218-226.
86. De Mos M, van der Windt AE, Jahr H et al. Can platelet-rich plasma enhance tendon repair? A cell culture study. *Am J Sports Med* 2008; 36:1171-1178.
87. Mishra A, Woodall J Jr, Vieira A. Treatment of tendon and muscle using platelet-rich plasma. *Clin Sports Med* 2009; 28:113-125.
88. Randelli PS, Arrigoni P, Ragone V, Aliprandi A, Cabitza P. Platelet rich plasma in arthroscopic rotator cuff repair: a prospective RCT study, 2-year follow-up. *J Shoulder Elbow Surg.* 2011; 20:518-528.
89. Al-Sady O, Schulze-Tanzil G, Kohl B, et al. Tenocytes, pro-inflammatory cytokines and leukocytes: a relationship? *MLTJ* 2011; 1:68-76.
90. Randelli PS, Arrigoni P, Ragone V, Aliprandi A, Cabitza P. Platelet rich plasma in arthroscopic rotator cuff repair: a prospective RCT study, 2-year follow-up. *J Shoulder Elbow Surg* 2011; 20:518-528.
91. Al-Sady O, Schulze-Tanzil G, Kohl B, et al. Tenocytes, pro-inflammatory cytokines and leukocytes: a relationship? *MLTJ* 2011; 1:68-76.
92. Del Buono A, Oliva F, Osti L, Maffulli N. Metalloproteases and tendinopathy *MLTJ* 2013; 3(1):51-57.